

# The American Journal of Sports Medicine

<http://ajs.sagepub.com/>

---

## **Superficial Medial Collateral Ligament Anatomic Augmented Repair Versus Anatomic Reconstruction: An In Vitro Biomechanical Analysis**

Coen A. Wijdicks, Max P. Michalski, Matthew T. Rasmussen, Mary T. Goldsmith, Nicholas I. Kennedy, Martin Lind, Lars Engebretsen and Robert F. LaPrade

*Am J Sports Med* 2013 41: 2858 originally published online September 13, 2013

DOI: 10.1177/0363546513503289

The online version of this article can be found at:

<http://ajs.sagepub.com/content/41/12/2858>

---

Published by:



<http://www.sagepublications.com>

On behalf of:

American Orthopaedic Society for Sports Medicine



**Additional services and information for *The American Journal of Sports Medicine* can be found at:**

**Email Alerts:** <http://ajs.sagepub.com/cgi/alerts>

**Subscriptions:** <http://ajs.sagepub.com/subscriptions>

**Reprints:** <http://www.sagepub.com/journalsReprints.nav>

**Permissions:** <http://www.sagepub.com/journalsPermissions.nav>

>> [Version of Record](#) - Nov 27, 2013

[OnlineFirst Version of Record](#) - Sep 13, 2013

[What is This?](#)

# Superficial Medial Collateral Ligament Anatomic Augmented Repair Versus Anatomic Reconstruction

## An In Vitro Biomechanical Analysis

Coen A. Wijdicks,\* PhD, Max P. Michalski,\* MSc, Matthew T. Rasmussen,\* BS, Mary T. Goldsmith,\* MSc, Nicholas I. Kennedy,\* BS, Martin Lind,<sup>†</sup> MD, PhD, Lars Engebretsen,<sup>‡</sup> MD, PhD, and Robert F. LaPrade,<sup>§||</sup> MD, PhD  
*Investigation performed at the Department of BioMedical Engineering of the Steadman Philippon Research Institute, Vail, Colorado*

**Background:** When surgical intervention is required for a grade 3 superficial medial collateral ligament (sMCL) tear, there is no consensus on the optimal surgical treatment. Anatomic augmented repairs and anatomic reconstructions for treatment of grade 3 sMCL tears have not been biomechanically validated or compared.

**Hypothesis:** Anatomic sMCL augmented repairs and anatomic sMCL reconstruction techniques will reproduce equivalent knee kinematics when compared with the intact state, while creating significant improvements in translational and rotational laxity compared with the sMCL sectioned state.

**Study Design:** Controlled laboratory study.

**Methods:** Eighteen match-paired, fresh-frozen cadaveric knees (average age, 52.6 years; range, 40-59 years) were each used to test laxity of an intact sMCL, a deficient sMCL, and either an anatomic augmented repair or an anatomic reconstruction. Knees were biomechanically tested in a 6 degrees of freedom robotic system, which included valgus rotation, internal and external rotation, simulated pivot shift, and coupled anterior drawer with external rotation.

**Results:** Anatomic augmented repairs and anatomic reconstructions had significantly less medial joint gapping than the sectioned state at all tested flexion angles and showed significant reductions in valgus rotation compared with the sectioned state at all flexion angles. No significant differences between the anatomic augmented repair and anatomic reconstruction were found for any test performed. Despite the similar behavior between the 2 reconstruction groups, neither technique was able to reproduce the intact state.

**Conclusion:** Anatomic sMCL augmented repairs and anatomic sMCL reconstructions were not significantly different when tested at time zero. Both the anatomic augmented repair and the anatomic reconstruction were able to improve knee stability and provide less than 2 mm of medial joint gapping at 0° and 20° of flexion.

**Clinical Significance:** These results suggest that both an anatomic sMCL augmented repair and an anatomic sMCL reconstruction improve knee kinematics compared with a deficient sMCL and provide equivalent joint stability.

**Keywords:** knee ligaments; MCL; superficial medial collateral ligament; augmented repair; anatomic reconstruction; valgus instability; biomechanics of ligament

The superficial medial collateral ligament (sMCL) has been reported to be the most commonly injured knee ligament, accounting for 42% of ligamentous knee injuries.<sup>3</sup> Although sMCL injury prevalence is high and most sMCL injuries are treated nonoperatively, recommendations for treatment

differ when nonoperative treatment fails or when surgical treatment is acutely required.<sup>4,10,18,32,34,43</sup> Anatomically imprecise graft placement and suboptimal reconstruction graft fixation methods can lead to overconstraint, residual instability, or graft loosening. Studies have attempted to optimize the surgical technique for the medial knee structures by providing thorough descriptions of the quantitative anatomic and biomechanical features.<sup>11-13,23,26,37,40</sup> These findings stress the importance of an anatomic restoration so that the native relationships within the knee can be fully

reestablished.<sup>28,29</sup> In recent years, a variety of different surgical methods and techniques have been reported to be successful for reconstructing the sMCL.<sup>16,29,35</sup> In the practices of the senior authors (M.L., L.E., R.F.L.), we have found it far more common to solely reconstruct the sMCL rather than combine its reconstruction with a posterior oblique ligament reconstruction. However, anatomically based augmented repairs or reconstructions of the isolated sMCL injury have not been biomechanically validated.

The sMCL functionally consists of 2 distinct divisions: a proximal division, which courses from the femur to the proximal tibial attachment, and a distal division, which courses between the 2 tibial attachments distally.<sup>11,33</sup> These divisions contribute synergistically to the overall function of the sMCL, with the proximal division functioning as a primary valgus stabilizer at all flexion angles and the distal division providing resistance to external rotation at higher flexion angles.<sup>11,12</sup> Thus, an anatomically based sMCL augmented repair or reconstruction would restore these functional relationships.

The most common complication after MCL-related surgical treatment is postoperative arthrofibrosis.<sup>27-29</sup> Because of a lack of anatomically based surgical techniques, discrepancy still remains regarding the optimal postoperative rehabilitation protocol. Most centers have followed a program of immobilization in full extension for up to 3 weeks to allow for healing of tissue, but this has led to a high risk of arthrofibrosis postoperatively.<sup>18,31,32,36</sup> The basis for postoperative immobilization is to prevent graft elongation after surgical treatment that could potentially lead to recurrent instability.<sup>39</sup> The rationale for immediate knee motion is that since a truly anatomic repair or reconstruction will minimize plastic deformation, immediate knee motion can be adapted to decrease the relatively high risk of arthrofibrosis that has been reported after MCL surgical treatment.<sup>27-29</sup> The effect of early postoperative motion programs on knee laxity at time zero, when an anatomic augmented repair or anatomic reconstruction is performed, is unknown. A time-zero study, with a rigorous postsurgical testing regimen, would provide baseline information regarding knee laxity and the feasibility of immediate postoperative motion. Additionally, it would provide insight into whether an anatomic augmented repair or anatomic reconstruction restores

knee kinematics and which may be best suited to undergo such immediate stresses.

The purpose of this study was to compare the kinematics of an anatomic sMCL augmented repair and anatomic sMCL reconstruction to the native intact and sectioned sMCL states by use of a robotic system. We hypothesized that both the anatomic augmented repair and reconstruction techniques would reproduce equivalent knee kinematics when compared with the intact state and would create significant improvements in translational and rotational laxity compared with the sMCL sectioned state.

## METHODS AND MATERIALS

### Specimen Preparation

A total of 18 match-paired fresh-frozen cadaveric knees (average age, 52.6 years; range, 40-59 years) without evidence of prior injury, abnormality, prior surgery, or disease, were used in this study based on their medical history and serology. Each specimen was thawed at room temperature for 24 hours before use. All soft tissue was removed from the distal end of the tibia and proximal end of the femur 10 cm from the joint line and potted with polymethylmethacrylate (Fricke Dental, Streamwood, Illinois). A superficial incision was made spanning from 6 cm proximal to the joint line to 8 cm distal to the joint line and coursing 4 cm medial to the medial aspect of the patella.

### Robotic System

Each knee was mounted, in an inverted orientation, in a 6 degrees of freedom (DOF) robotic system (KR 60-3, KUKA Robotics, Augsburg, Germany) before surgical and biomechanical testing procedures.<sup>9</sup> A custom fixture attached the tibia to a universal force-torque sensor (Delta F/T Transducer, ATI Industrial Automation, Apex, North Carolina) at the end effector of the robotic system. Anatomic landmarks on the knee were selected with a coordinate measuring machine (MicroScribe MX-GoMeasure3D, Amherst, Virginia) to define a coordinate system for the tibia, femur, and knee.<sup>14,41</sup>

§Address correspondence to Robert F. LaPrade, MD, PhD, The Steadman Clinic, 181 West Meadow Drive, Suite 400, Vail, CO 81657 (e-mail: drlaprade@sprivail.org).

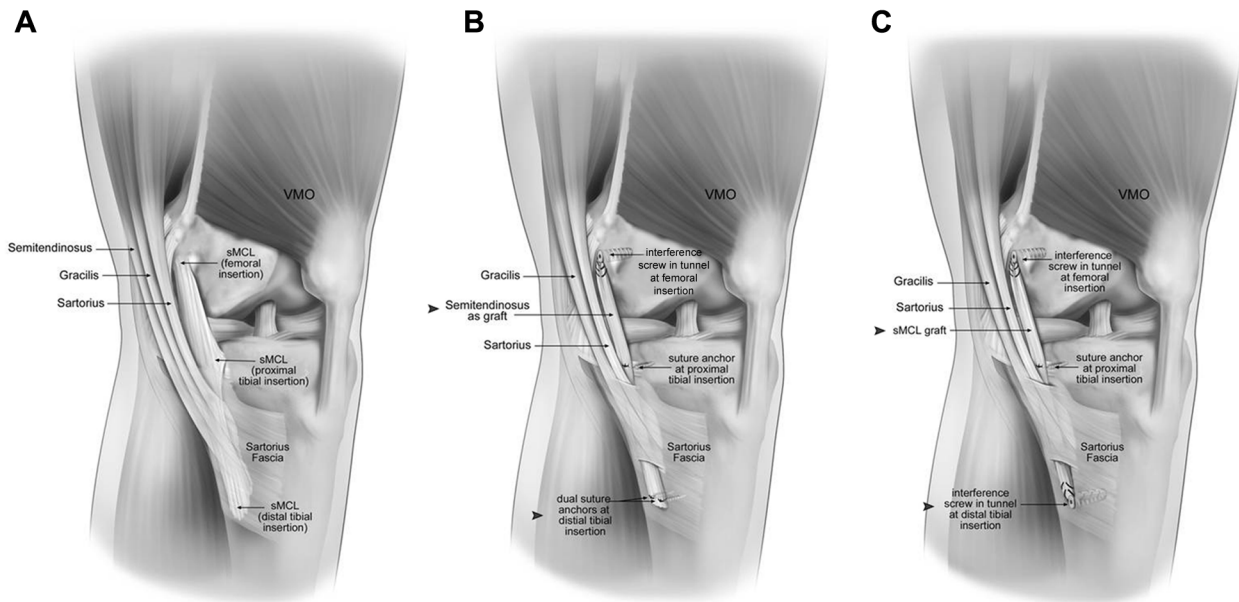
\*Department of BioMedical Engineering, Steadman Philippon Research Institute, Vail, Colorado.

†University of Aarhus, Aarhus, Denmark.

‡Department of Orthopaedic Surgery, Oslo University Hospital and Faculty of Medicine, University of Oslo, Oslo, Norway.

||The Steadman Clinic, Vail, Colorado.

One or more of the authors has declared the following potential conflict of interest or source of funding: This research was partially supported through a postdoctoral fellowship grant from the Norwegian Health South-East (Helse Sør-Øst) Regional Health Authority and a grant from Aarhus University Hospital Foundation for Sportstraumatology. This research was also supported by the Steadman Philippon Research Institute, a 501(c)(3) nonprofit institution which has received material donations for this study from the following: Arthrex Inc and Smith & Nephew. R.F.L. has received from Arthrex, ConMed Linvatec, Smith & Nephew Endoscopy, and Ossur something of value (exceeding the equivalent of US\$500) not related to this manuscript or this research; he acts as a consultant for Arthrex and has received research support in the past for other various research projects from all four companies listed previously. L.E. has received from Arthrex, Smith & Nephew, Fin-Ceramina, and TBF Tissue Engineering something of value (exceeding the equivalent of US\$500) not related to the manuscript or this research; he acts as a consultant for Arthrex and has received research support in the past from all four companies listed previously.



**Figure 1.** Anteromedial view of left knee. (A) The superficial medial collateral ligament (sMCL) is shown with the location of the femoral origin and the proximal and distal tibial insertions of the sMCL. Also displayed are the pes anserine tendons (sartorius, gracilis, and semitendinosus) coursing distally to their insertion on the tibia anterior to the distal sMCL insertion. Further note the sartorius fascia overlying the distal sMCL. (B) Anatomic augmented repair of the sMCL in a left knee. Distal tibial fixation of the semitendinosus was performed with 2 double-loaded suture anchors by suturing the semitendinosus to the sMCL remnant 6 cm distal to the joint line. The semitendinosus tendon was passed deep to the sartorius fascia. Anatomic fixation of the femoral tunnel 3.2 mm proximal and 4.8 mm posterior to the medial epicondyle was performed with 60 N of traction applied to the graft at 20° of knee flexion and neutral rotation. Proximal tibial fixation was located 12 mm distal to the joint line and directly over the most anterodistal attachment of the anterior arm of the semimembranosus. (C) Anatomic reconstruction of the sMCL. Femoral and distal tibial fixation achieved with an interference screw. Proximal tibial fixation performed with a suture anchor 12 mm distal to the joint line. Arrowheads in (B) and (C) highlight differences between the anatomic augmented repair and anatomic reconstruction techniques. VMO, vastus medialis obliquus.

### Biomechanical Testing

Each knee's passive flexion path was determined from 0° (or full extension) to 90° by selecting zero force locations along the flexion path in 1° increments. For each flexion angle, forces and torques in the remaining 5 DOF were minimized (<5 N and <0.5 N·m, respectively), while an axial force of 10 N was applied to ensure contact between the femur and tibia. The passive path tibiofemoral positions were recorded and used as the starting points for subsequent biomechanical testing.

For biomechanical testing, robotic force and position control were used to replicate clinical examinations through a range of flexion angles.<sup>9,30</sup> All examinations were performed at 0°, 20°, 30°, 60°, and 90° of knee flexion. Valgus rotation was measured during a 10-N·m valgus torque applied to the tibia.<sup>11</sup> Medial gapping was determined by calculating increases in the translation at the center of the medial compartment of the tibiofemoral joint during applied valgus torques compared with the intact state.<sup>25</sup> The center of the medial compartment of the tibial plateau was calculated as equidistant between the center of the tibial plateau and the medial-most palpable point of the tibia at the joint line, which was based on the position used clinically to measure valgus stress radiographs.<sup>25</sup>

Additionally, rotation limits of the knees were measured with applied 5-N·m internal rotation and 5-N·m external rotation torques.<sup>2,4,12</sup> Rotational laxity in response to combined rotatory motion was tested with a simulated pivot shift, consisting of a coupled 10-N·m valgus torque followed by a 5-N·m internal rotation torque, and with a coupled 88-N anterior drawer force and a 5-N·m external rotation torque.<sup>8,22,33,42</sup> Each testing series was repeated on the intact (Figure 1A), sectioned, and augmented/reconstructed states (Figure 1, B and C). The flexion angle testing order was randomized between specimens to prevent incremental testing bias.

### Surgical sMCL Sectioning Technique

The anatomic attachment sites of the sMCL on the femur and tibia were identified through the superficial incision and marked with a surgical marking pen.<sup>38</sup> After intact state testing, the sMCL was excised between its femoral and distal tibial attachments, leaving the distal tibial attachment remnant intact, for the sectioned state, which simulated a grade 3 sMCL injury before an augmented repair or reconstruction.<sup>39</sup> The posterior oblique ligament and deep MCL were left intact.

## Anatomic Semitendinosus sMCL Augmented Repair

All sMCL reconstructions and augmented repairs were performed by a single, experienced, board-certified sports medicine orthopaedic surgeon (R.F.L.). Right and left knees were randomized between the anatomic augmented repair and anatomic reconstruction groups. To reduce testing error introduced from specimen removal, all reconstructions were performed while the knee remained fixed in the robot.

The sartorius fascia was left intact. The semitendinosus tendon was identified at its tibial attachment, and an open-ended hamstring stripper detached it proximally. The tendon was then anchored to the tibia at the sMCL distal tibial attachment, 6 cm distal to the joint line,<sup>26</sup> with 2 double-loaded suture anchors (Corkscrew FT, Arthrex Inc, Naples, Florida) and was further sutured to the underlying remnant of the distal aspect of the sMCL (Figure 1B). The tendon was then passed deep to the sartorius fascia up to the femoral attachment of the sMCL, which has been reported to be 3.2 mm proximal and 4.8 mm posterior to the medial epicondyle.<sup>26</sup> The femoral tunnel was reamed over an eyelet pin, previously drilled anterolaterally across the femur, with a 7-mm reamer to a depth of 25 mm. The semitendinosus graft was then measured to fit into this tunnel; the end was whip-stitched with braided polypropylene No. 2 sutures (FiberWire, Arthrex Inc), and the excess length of the graft was amputated before the graft was passed into the femoral tunnel. While a 60-N traction force was applied to the graft, a 7 × 25-mm polyether ether ketone (PEEK) interference screw (BIOSURE PK, Smith & Nephew, Andover, Massachusetts) was used to secure the sMCL graft in the femoral tunnel with the knee positioned at 20° of flexion and neutral rotation in the robot, while the clinician applied a varus reduction torque of approximately 10 N·m.<sup>25</sup> Finally, a 5 × 15-mm double-loaded suture anchor (Corkscrew FT) was used to anatomically restore the proximal tibial division of the sMCL 12 mm distal to the joint line and directly over the most anterodistal attachment of the anterior arm of the semimembranosus.<sup>4,26,38,39</sup>

## Anatomic sMCL Reconstruction

Similar to the repair technique, the anatomic sMCL reconstruction technique left the sartorius fascia in place. The femoral and distal tibial attachment sites were identified and the femoral attachment site tunnel was prepared in a manner similar to that used for the anatomic augmented repair technique. A tibial reconstruction tunnel was placed 6 cm distal to the joint line in the center of the distal tibial sMCL attachment (Figure 1C). A 7-mm-diameter tunnel was reamed over an eyelet pin passed anterolaterally to a depth of 25 mm.

Fresh-frozen bovine digital extensor graft (IMDS Discovery Research, Logan, Utah) of 16 cm in total length and sized to a diameter of 7 mm was whip-stitched with braided polypropylene sutures 25 mm from both ends. The prepared graft was passed into the tibial tunnel and secured in place with a 7 × 25-mm PEEK screw. Bovine digital extensor

tendons were used because they have been reported to have viscoelastic, structural, and material properties similar to those of human semitendinosus tendons.<sup>6</sup> Furthermore, bovine digital extensor tendons were used as a surrogate in several previous human knee ligament biomechanics studies because of their uniform size and diameter compared with human hamstring tendons.<sup>1,5,7,15,24</sup>

Once the sMCL graft was fixed in the distal tibial reconstruction tunnel, the knee was positioned at 20° of flexion and neutral rotation in the robot, and a varus reduction force was manually applied. The graft was then passed into the femoral tunnel and fixed with a 7 × 25-mm PEEK screw while 60 N of traction was applied with a graft tensioning device. The 60-N traction force was chosen and standardized based on the clinical practice of the senior authors. After fixation of both the distal tibial and femoral attachments, a double-loaded suture anchor was used to fix the proximal tibial attachment site in a manner similar to that used for the anatomic augmented repair technique outlined above.

## Pilot Testing

During initial pilot testing, 2 different anatomic augmented femoral fixation repair techniques were used. Two suture anchors were used proximally to attach the augmented graft to the femoral sMCL origin and were compared with an interference screw femoral reconstruction tunnel. Pilot robotic testing of 4 match-paired knees resulted in a failure of the knees with suture anchor femoral fixation; knees with a proximal suture anchor fixation were similar to the sectioned state. An anatomic technique that could withstand the rigors of early postoperative motion was desired, which was theoretically replicated by our rigorous testing protocol in the robot. Therefore, we thought an anatomic augmented repair technique that used suture anchors as the femoral fixation was not valid and we compared the femoral tunnel anatomic augmented repair with a complete sMCL anatomic reconstruction instead.

## Statistical Analysis

Twice during the testing phase, statistical power calculations were made to estimate the necessary sample size to detect differences between the sectioned and repaired or reconstructed states. All statistical comparisons of interest were preplanned and pairwise, and it was not assumed that group standard deviations could be pooled. Thus, Student *t* tests were chosen over analysis of variance (ANOVA) models. One-sample *t* tests were performed to compare the sectioned, anatomic sMCL augmented repair, and anatomic sMCL reconstruction groups individually to the intact state. Two-sample independent *t* tests were used for comparison between the anatomic augmented repair and anatomic reconstruction. In all cases, the Levene test was used to check for equality of variance, and the Welch *t* test was used when groups had significantly different variances. Differences were considered significant when  $P < .05$ , and no adjustments were made for multiple comparisons.

TABLE 1  
Valgus Rotation, Medial Joint Gapping, External Rotation, and Internal Rotation Values for Intact States and Differences From Intact: sMCL-Sectioned, Anatomic Reconstruction, and Anatomic Augmented Repair States<sup>a</sup>

Flexion Angle	Applied 10-N-m Valgus Rotation Torque				Applied 10-N-m Valgus Rotation Torque			
	Valgus Rotation, deg	Difference From Intact, deg			Medial Joint Gapping, mm	Difference From Intact, mm		
	Intact (n = 18)	Sectioned (n = 18)	Reconstruction (n = 9)	Repair (n = 9)	Intact (n = 18)	Sectioned (n = 18)	Reconstruction (n = 9)	Repair (n = 9)
0°	3.8 ± 0.9	4.1 ± 2.5 <sup>f</sup>	1.5 ± 1.6 <sup>L,S</sup>	1.9 ± 1.6 <sup>L,S</sup>	2.4 ± 0.6	3.3 ± 1.8 <sup>f</sup>	1.2 ± 1.3 <sup>f,S</sup>	1.6 ± 1.4 <sup>f,S</sup>
20°	5.4 ± 2.0	5.3 ± 3.0 <sup>f</sup>	2.4 ± 2.2 <sup>L,S</sup>	2.5 ± 1.4 <sup>L,S</sup>	3.0 ± 0.9	4.6 ± 2.3 <sup>f</sup>	1.8 ± 1.9 <sup>f,S</sup>	1.9 ± 1.3 <sup>f,S</sup>
30°	6.2 ± 2.7	5.4 ± 2.8 <sup>f</sup>	2.7 ± 2.3 <sup>L,S</sup>	2.6 ± 1.4 <sup>L,S</sup>	3.1 ± 1.1	5.0 ± 2.1 <sup>f</sup>	2.2 ± 2.1 <sup>f,S</sup>	2.2 ± 1.5 <sup>f,S</sup>
60°	7.7 ± 3.9	6.5 ± 3.1 <sup>f</sup>	1.3 ± 1.9 <sup>S</sup>	1.5 ± 2.1 <sup>S</sup>	3.5 ± 1.5	5.1 ± 2.0 <sup>f</sup>	1.0 ± 1.7 <sup>S</sup>	1.6 ± 1.8 <sup>f,S</sup>
90°	9.0 ± 4.2	5.2 ± 3.3 <sup>f</sup>	1.6 ± 2.2 <sup>S</sup>	1.8 ± 2.1 <sup>L,S</sup>	3.9 ± 1.8	4.1 ± 1.7 <sup>f</sup>	1.1 ± 1.9 <sup>S</sup>	1.4 ± 1.7 <sup>f,S</sup>

Flexion Angle	Applied 5-N-m External Rotation Torque				Applied 5-N-m Internal Rotation Torque			
	External Rotation, deg	Difference From Intact, deg			Internal Rotation, deg	Difference From Intact, deg		
	Intact (n = 18)	Sectioned (n = 18)	Reconstruction (n = 9)	Repair (n = 9)	Intact (n = 18)	Sectioned (n = 18)	Reconstruction (n = 9)	Repair (n = 9)
0°	14.9 ± 5.0	4.3 ± 1.7 <sup>f</sup>	2.2 ± 1.2 <sup>L,S</sup>	1.3 ± 2.2 <sup>S</sup>	13.2 ± 3.2	4.8 ± 3.3 <sup>f</sup>	3.1 ± 2.2 <sup>f</sup>	3.8 ± 1.6 <sup>f</sup>
20°	18.7 ± 6.8	5.8 ± 2.5 <sup>f</sup>	3.1 ± 1.8 <sup>L,S</sup>	1.8 ± 2.5 <sup>S</sup>	19.6 ± 5.5	6.3 ± 4.0 <sup>f</sup>	3.9 ± 2.7 <sup>f</sup>	4.6 ± 1.5 <sup>f</sup>
30°	19.8 ± 8.3	7.1 ± 2.7 <sup>f</sup>	4.3 ± 2.5 <sup>L,S</sup>	2.6 ± 2.9 <sup>L,S</sup>	21.6 ± 6.3	6.6 ± 3.8 <sup>f</sup>	4.9 ± 4.3 <sup>f</sup>	4.5 ± 1.9 <sup>f</sup>
60°	19.9 ± 9.2	10.5 ± 3.5 <sup>f</sup>	4.8 ± 3.7 <sup>L,S</sup>	3.1 ± 4.0 <sup>L,S</sup>	21.5 ± 7.4	4.1 ± 2.1 <sup>f</sup>	1.1 ± 3.2 <sup>S</sup>	2.2 ± 2.0 <sup>f,S</sup>
90°	20.9 ± 8.4	10.0 ± 2.9 <sup>f</sup>	4.0 ± 3.4 <sup>L,S</sup>	2.2 ± 3.5 <sup>S</sup>	20.6 ± 7.7	2.7 ± 2.0 <sup>f</sup>	0.4 ± 3.6 <sup>S</sup>	1.1 ± 1.7

<sup>a</sup>Values are expressed as mean ± standard deviation. sMCL, superficial medial collateral ligament.

<sup>f</sup>Significant difference when compared with intact state ( $P < .05$ ).

<sup>S</sup>Significant difference when compared with the sMCL-sectioned state ( $P < .05$ ).

Equivalence tests performed with the confidence interval method were used to determine whether medial gapping during an applied valgus torque at clinically relevant flexion angles could be considered clinically equivalent for anatomic sMCL augmented repair and anatomic sMCL reconstructions. As described by Harris et al,<sup>17</sup> 90% confidence intervals were constructed for each difference between augmented repair and reconstruction to achieve a type I error rate of  $\alpha = .05$ . This calculated confidence interval (CI) was compared with a minimal level of clinically distinguishable differences. If the CI fell completely below the threshold for the minimal level of clinically important difference, then the two reconstructions were considered equivalent. The clinical cutoff for equivalence was set at the upper limit of variation between normal knees, or 2.0 mm, according to the International Knee Documentation Committee (IKDC) 2000 Knee Examination.<sup>19</sup> Difference testing was performed with SPSS (IBM SPSS Statistics for Windows, version 21.0, IBM Corp, Armonk, New York), while equivalence calculations were performed with the statistical computing software R (R version 2.15.2, R Foundation for Statistical Computing, Vienna, Austria) using the equivalence package (R package version 0.5.6, Andrew Robinson, 2010).

## RESULTS

A comprehensive, quantitative list of all testing results is located in Tables 1 and 2 and includes the intact values and results of the sectioned, anatomic augmented repair,

and anatomic reconstruction states relative to intact. Results are reported as significantly different from intact, from sectioned, and between repair and reconstruction states. The sectioned state was significantly different from the intact state at all flexion angles for all conditions tested ( $P < .05$ ). The anatomic augmented repair and reconstruction were not significantly different from each other at any flexion angle for all conditions tested. The most clinically pertinent findings are listed below, and the average differences between groups are used for comparison.

### Valgus Rotation

The anatomic augmented repair had significant reductions in valgus rotation compared with the sectioned state at all flexion angles tested ( $P < .05$ ). Similarly, the anatomic reconstruction had significantly less valgus rotation than the sectioned state at all flexion angles tested. Decreases in valgus rotation compared with the sectioned state averaged 2.2° and 2.8° ( $P < .05$ ) at 0° and 20° of flexion for the anatomic augmented repair and 2.5° and 2.9° ( $P < .05$ ) for the anatomic reconstruction groups. The significant differences from intact were 1.9° and 2.5° ( $P < .05$ ) at 0° and 20° of flexion for the anatomic augmented repair and 1.5° and 2.4° ( $P < .05$ ) for the anatomic reconstruction groups (Table 1).

### Medial Joint Gapping

Both the anatomic augmented repair and anatomic reconstruction had significantly less medial joint gapping than

TABLE 2  
Anteromedial Drawer and Simulated Pivot Shift Values for Intact States and Differences From Intact: sMCL-Sectioned, Anatomic Reconstruction, and Anatomic Augmented Repair States<sup>a</sup>

Flexion Angle	Coupled 100-N Anterior Load and 5-N·m External Rotation Torque				Coupled 100-N Anterior Load and 5-N·m External Rotation Torque			
	Axial Plane Translation, mm		Difference From Intact, mm		External Rotation, deg		Difference From Intact, deg	
	Intact (n = 18)	Sectioned (n = 18)	Reconstruction (n = 9)	Repair (n = 9)	Intact (n = 18)	Sectioned (n = 18)	Reconstruction (n = 9)	Repair (n = 9)
0°	6.3 ± 1.9	0.8 ± 0.8 <sup>i</sup>	0.4 ± 0.5	0.3 ± 0.7	14.5 ± 5.0	4.4 ± 1.7 <sup>i</sup>	2.0 ± 1.6 <sup>i,S</sup>	1.4 ± 2.4 <sup>S</sup>
20°	7.7 ± 2.6	1.2 ± 1.3 <sup>i</sup>	0.8 ± 1.2	0.4 ± 0.9	18.4 ± 6.7	6.0 ± 2.6 <sup>i</sup>	3.4 ± 2.4 <sup>i,S</sup>	1.5 ± 2.7 <sup>S</sup>
30°	8.0 ± 3.0	1.6 ± 1.7 <sup>i</sup>	0.9 ± 2.0	0.9 ± 1.0 <sup>i</sup>	19.6 ± 8.2	7.4 ± 2.7 <sup>i</sup>	4.4 ± 2.7 <sup>i,S</sup>	2.5 ± 2.8 <sup>i,S</sup>
60°	6.2 ± 3.6	3.5 ± 2.5 <sup>i</sup>	2.4 ± 2.7 <sup>i</sup>	1.5 ± 1.9 <sup>i,S</sup>	18.9 ± 9.0	12.0 ± 4.4 <sup>i</sup>	5.4 ± 5.2 <sup>i,S</sup>	3.3 ± 5.1 <sup>S</sup>
90°	5.2 ± 3.7	3.7 ± 1.9 <sup>i</sup>	1.7 ± 2.5 <sup>S</sup>	1.7 ± 1.8 <sup>i,S</sup>	19.3 ± 8.0	11.9 ± 3.2 <sup>i</sup>	3.5 ± 4.7 <sup>S</sup>	2.8 ± 4.7 <sup>S</sup>

Flexion Angle	Simulated Pivot Shift				Simulated Pivot Shift			
	Internal Rotation, deg		Difference From Intact		Anterior Translation, mm		Difference From Intact	
	Intact (n = 18)	Sectioned (n = 18)	Reconstruction (n = 9)	Repair (n = 9)	Intact (n = 18)	Sectioned (n = 18)	Reconstruction (n = 9)	Repair (n = 9)
0°	13.9 ± 3.3	7.0 ± 4.6 <sup>i</sup>	3.6 ± 2.5 <sup>i</sup>	5.0 ± 1.9 <sup>i</sup>	0.4 ± 1.1	-1.5 ± 1.2 <sup>i</sup>	-0.6 ± 0.8 <sup>S</sup>	-1.2 ± 0.6 <sup>i</sup>
20°	20.8 ± 5.8	7.3 ± 4.0 <sup>i</sup>	4.8 ± 2.3 <sup>i</sup>	5.1 ± 1.9 <sup>i</sup>	1.4 ± 1.8	-2.0 ± 2.0 <sup>i</sup>	-1.5 ± 0.8 <sup>i</sup>	-1.3 ± 0.5 <sup>i</sup>
30°	22.8 ± 6.6	6.7 ± 4.6 <sup>i</sup>	5.3 ± 4.0 <sup>i</sup>	4.1 ± 2.6 <sup>i</sup>	1.4 ± 1.8	-2.2 ± 1.2 <sup>i</sup>	-1.8 ± 1.2 <sup>i</sup>	-1.4 ± 0.7 <sup>i</sup>

<sup>a</sup>Values are expressed as mean ± standard deviation. sMCL, superficial medial collateral ligament.

<sup>i</sup>Significant difference when compared with intact state ( $P < .05$ ).

<sup>S</sup>Significant difference when compared with the sMCL-sectioned state ( $P < .05$ ).

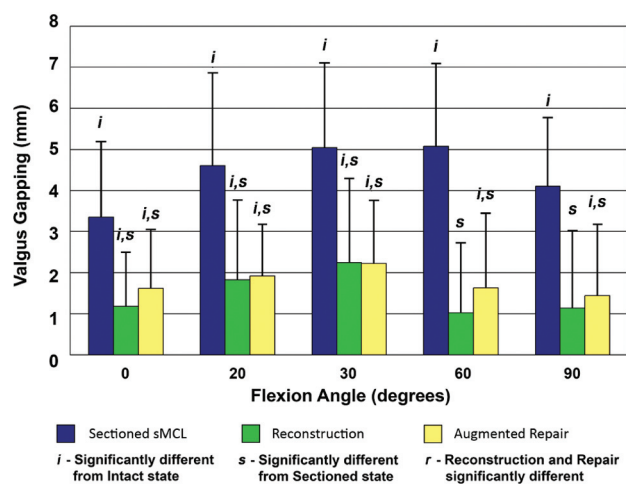


Figure 2. Changes in medial compartment gapping after sectioning, anatomic superficial medial collateral ligament (sMCL) augmented repair, and anatomic sMCL reconstruction. Data are reported as an average increase in medial compartment gapping compared with the intact knee in response to a 10-N·m valgus torque.

the sectioned state at all tested flexion angles. Compared with the sectioned state, the decrease in medial joint gapping at 20° and 30° of flexion averaged 2.7 mm and 2.8 mm ( $P < .01$ ) for the anatomic augmented repair and 2.8 mm and 2.8 mm ( $P < .01$ ) for the anatomic reconstruction. The significant differences from intact were 1.9 mm and

2.2 mm ( $P < .05$ ) at 20° and 30° of flexion for the anatomic augmented repair and 1.8 mm and 2.2 mm ( $P < .05$ ) for the anatomic reconstruction groups (Figure 2 and Table 1).

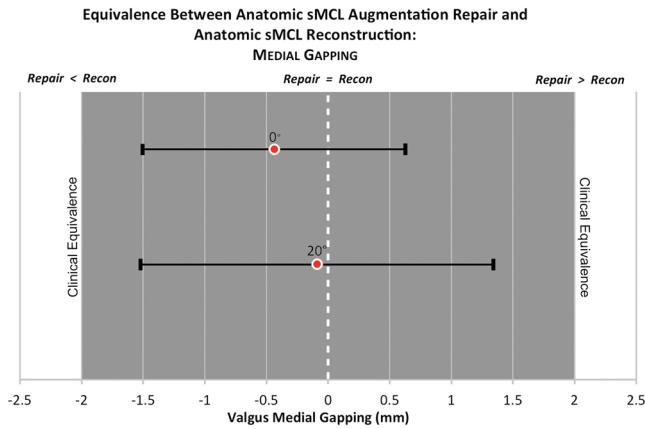
The equivalence test using the confidence interval for differences between anatomic augmented repair and anatomic reconstruction demonstrated that the two techniques can be considered clinically equivalent at 0° and 20° (Figure 3). Additionally, differences between the groups (mean ± SD;  $0.4 \pm 1.7$  mm for 0° and  $0.1 \pm 2.3$  mm for 20°) can be compared with the intraspecimen variability for changes in medial gapping, which was found to be 0.8 mm averaged over all specimen pairs at 0° and 20° of flexion.

### External Rotation

The anatomic augmented repair and anatomic reconstruction displayed significantly less external rotation than the sectioned state at all flexion angles tested. The average decrease in external rotation, compared with the sectioned state average at 30° and 90° of flexion (dial test), was 4.4° and 7.9° ( $P < .01$ ) for the anatomic augmented repair and 2.8° and 6.1° ( $P < .01$ ) for the anatomic reconstruction. The significant differences from intact were 2.6° ( $P < .05$ ) at 30° of flexion for the anatomic augmented repair and 4.3° and 4.0° ( $P < .05$ ) at 30° and 90° of flexion for the anatomic reconstruction groups (Figure 4 and Table 1).

### Internal Rotation

The anatomic augmented repair had a significant reduction of 1.9° ( $P < .05$ ) of internal rotation when compared



**Figure 3.** Equivalence test of medial joint gapping in anatomic superficial medial collateral ligament (sMCL) augmented repair and anatomic sMCL reconstruction at 0° and 20° of knee flexion. The clinical cutoff for equivalence was set at 2 mm, which is the upper limit of difference from the contralateral knee in the International Knee Documentation Committee 2000 Knee Examination.

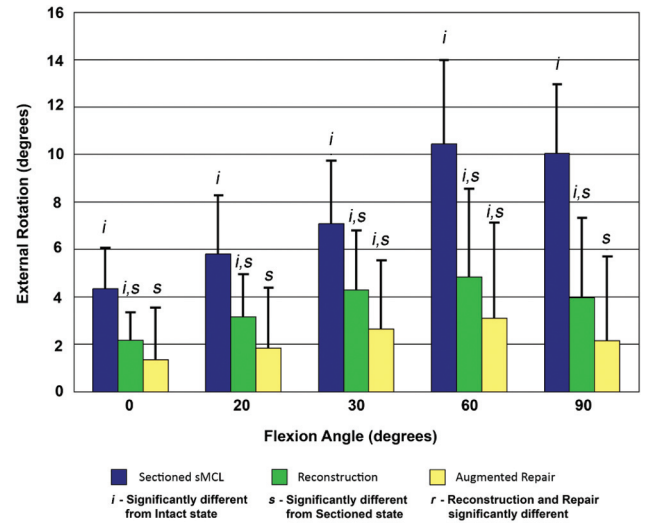
with the sectioned state at 60° of flexion. The anatomic reconstruction had significantly reduced internal rotation compared with the sectioned state at 60° and 90° of flexion. At 0° of flexion, the significant differences from intact were 3.8° and 3.1° ( $P < .01$ ) for the anatomic augmented repair and anatomic reconstruction, respectively (Table 1).

**Anteromedial Drawer**  
(Anterior Drawer With External Rotation)

The anatomic augmented repairs and anatomic reconstructions significantly reduced knee translation on average by 2.1 mm and 2.0 mm ( $P < .05$ ), respectively, compared with the average sectioned state at 90° of flexion, where the anteromedial drawer test is performed clinically. Additionally, the anatomic augmented repairs and anatomic reconstructions significantly reduced knee rotation at all tested flexion angles compared with the sectioned state. At 90° of flexion, external rotation was on average reduced by 9.2° ( $P < .05$ ) for the anatomic augmented repair and 8.5° ( $P < .05$ ) for the anatomic reconstruction compared with the sectioned sMCL. With regard to translation, the anatomic augmentation repair resulted in a significant difference from intact of  $1.7 \pm 1.8$  mm ( $P < .05$ ) at 90° (Table 2). At 90°, external rotation resulted in differences from intact of 2.8° and 3.5° for the anatomic augmentation repair and anatomic reconstruction, respectively; however, these were not significant.

**Simulated Pivot Shift (Internal and Valgus Rotations)**

The anatomic reconstruction significantly reduced anterior translation by 0.9 mm ( $P < .05$ ) during applied internal rotation and valgus rotation torques at 0° of knee flexion compared with the sectioned state. For all tested flexion



**Figure 4.** Changes in external rotation after sectioning, anatomic superficial medial collateral ligament (sMCL) augmented repair, and anatomic sMCL reconstruction. Data are reported as average increase in external rotation compared with the intact knee in response to a 5-N·m external rotation torque.

angles, the anatomic augmented repair and anatomic reconstruction both had significant differences from the intact state in anterior translation and internal rotation during an applied simulated pivot shift, except for the anatomic reconstruction at 0°, which was not significantly different from intact (Table 2).

**DISCUSSION**

We found that both an anatomic sMCL augmented repair and an anatomic sMCL reconstruction improved knee stability when compared with a sectioned sMCL. Medial joint gapping, valgus rotation, and external rotation were significantly reduced from the sectioned state. Further, these results were recorded after a rigorous testing protocol with the robot manipulating the knee in a much more aggressive fashion than would be seen in a typical physical therapy regimen. Therefore, the ability to significantly improve from the sectioned state may substantiate the ability to initiate joint motion immediately postoperatively. Early joint motion is crucial to maintaining the mechanical properties and prevents disorganization of collagen fibrils.<sup>21</sup> The ability to initiate postoperative mobilization allows for return of knee function while minimizing the development of arthrofibrosis.<sup>27-29</sup>

The pilot study demonstrated that an aggressive early knee motion program, as evaluated by the rigorous robotic knee testing cycles, did not significantly stretch out the anatomic augmented repair. However, the proximal sMCL augmented repair with suture anchors, which lacked a reconstruction tunnel and which the senior author often used clinically, had failed at time zero. These findings have led to an immediate change in the senior author's clinical practice.



We found that the anatomic augmented sMCL repair and reconstruction techniques both restored normal laxity of the knee for a number of the tested conditions. We do not believe that the residual laxity found after either of these two surgical techniques will be of clinical importance. It is our opinion that further improvements in medial knee stability after injury should still be sought in the future with additional refinements in anatomic reconstruction principles.

The results of medial knee gapping and valgus rotation with an applied valgus stress to the sMCL sectioned knee are similar to results reported previously.<sup>11,25,28,43</sup> Griffith et al<sup>11</sup> reported increases in valgus rotations after complete sMCL sectioning of 3°, 7°, 6.5°, 8.5°, and 5° when compared with intact at 0°, 20°, 30°, 60°, and 90° of knee flexion respectively, which compares well with valgus rotational differences observed here (4.1°-6.5°). LaPrade et al<sup>25</sup> reported an average of 3.8 mm and 6.0 mm of side-to-side difference in medial knee gapping when comparing the intact knee to the sMCL-deficient knee; these differences were determined by valgus stress radiographs at 0° and 20° of knee flexion, respectively, in cadaveric specimens with an applied 10-N·m valgus torque. A clinical outcomes study reported an increase in medial joint gapping of 6.2 mm on valgus stress radiographs at 20° of knee flexion in patients presenting with instability during activities of daily living.<sup>28</sup> The current study observed an increase in medial gapping after complete sectioning of 3.3 mm and 4.6 mm when compared with the intact state, which was less than the previous studies but may be accounted for by the additional removal of the meniscotibial ligament in the cadaveric study<sup>25</sup> and the need for reconstruction of the posterior oblique ligament in the patients presenting with instability.<sup>28</sup> Yoshiya et al<sup>43</sup> reported medial knee gapping of 3 to 6 mm when compared with the uninjured knee, determined by valgus stress radiographs at 20° of knee flexion, in patients presenting for surgery because of chronic medial knee instability or gross medial instability on clinical valgus stress examination. This compares well with our results for medial knee gapping at 0° and 20° of knee flexion, where we found 3.3 mm and 4.6 mm more medial gapping for the sectioned state compared with the intact state. The Yoshiya et al<sup>43</sup> study reported an increase of 1.7 mm and 1.8 mm when compared with the intact state after sectioning of the proximal sMCL and distal sMCL, respectively, at 0° of knee flexion and 2.8 mm and 2.7 mm when examined at 20° of knee flexion with a 10-N·m applied valgus load. The combined contributions of laxity from these two structures are similar to our observed results for the sectioned state.

Compared with results previously reported in the literature, we found more external rotation at 0° and 20° of knee flexion and less internal rotation at 30°, 60°, and 90°.<sup>11</sup> These differences in internal and external rotation may be a result of the experimental setup. Use of a 6-DOF robot allows for determination of a passive path in which the forces throughout the knee are minimized at each testing position. These positions may differ from other studies in which the knee was manually manipulated to determine neutral rotation positions.

The strengths of this study include the use of a highly accurate and repeatable robotic testing system, matched-

pair specimens, and surgeries performed by the same sports medicine orthopaedic surgeon with experience in these surgical techniques. The robotic testing system generated highly repeatable movements by applying the same forces for clinical examination maneuvers each time. Use of matched-pair specimens helps to eliminate bias between specimens because differences are minimized within paired knees.<sup>20</sup> Surgical repair or reconstruction performed by the same experienced orthopaedic surgeon for all specimens helps limit any variability between surgeon skill and technique.

The limitations of this study include the fact that it is a time-zero cadaveric biomechanics study, and the strenuous robotic testing protocol was performed immediately after the surgical procedures. Inherent to any in vitro biomechanics study is the fact that no biologic repair or remodeling occurs. While the grafts used were bovine extensor tendons, they have previously been reported to have similar properties as human semitendinosus tendons.<sup>6</sup>

In conclusion, the anatomic sMCL augmented repair and anatomic sMCL reconstruction were not significantly different from each other when tested in an in vitro setting. Both anatomically based sMCL surgical treatment techniques were also biomechanically validated to reduce knee laxity. Further, the ability to withstand a rigorous robotic testing protocol and maintain improvements in stability suggests the ability to withstand immediate postoperative motion in rehabilitation. An improved understanding of biomechanical stability after anatomic sMCL reconstruction or repair techniques can serve as the foundation for future biomechanical and clinical studies. Despite the similar behavior between the 2 reconstruction groups, neither technique was able to reproduce the intact state. While anatomic augmented repairs and reconstructions are similar at time zero, an evidence level 1 clinical trial is recommended to determine whether there are differences in short- or long-term clinical outcomes both objectively with valgus stress radiographs and through the use of patient-reported outcome scores.

## ACKNOWLEDGMENT

The authors thank Grant Dornan for work on the statistical analysis, Angelica Wedell for assistance with figures, and Andy Evansen for figure illustrations.

## REFERENCES

1. Ahmad CS, Gardner TR, Groh M, Arnouk J, Levine WN. Mechanical properties of soft tissue femoral fixation devices for anterior cruciate ligament reconstruction. *Am J Sports Med.* 2004;32(3):635-640.
2. Anderson CJ, Westerhaus BD, Pietrini SD, et al. Kinematic impact of anteromedial and posterolateral bundle graft fixation angles on double-bundle anterior cruciate ligament reconstructions. *Am J Sports Med.* 2010;38(8):1575-1583.
3. Bollen S. Epidemiology of knee injuries: diagnosis and triage. *Br J Sports Med.* 2000;34(3):227-228.
4. Coobs BR, Wijdicks CA, Armitage BM, et al. An in vitro analysis of an anatomical medial knee reconstruction. *Am J Sports Med.* 2010;38(2):339-347.

5. Cuomo P, Rama KR, Bull AM, Amis AA. The effects of different tensioning strategies on knee laxity and graft tension after double-bundle anterior cruciate ligament reconstruction. *Am J Sports Med.* 2007;35(12):2083-2090.
6. Donahue TL, Gregersen C, Hull ML, Howell SM. Comparison of viscoelastic, structural, and material properties of double-looped anterior cruciate ligament grafts made from bovine digital extensor and human hamstring tendons. *J Biomech Eng.* 2001;123(2):162-169.
7. Ehrensberger M, Hohman DW Jr, Duncan K, Howard C, Bisson L. Biomechanical comparison of femoral fixation devices for anterior cruciate ligament reconstruction using a novel testing method. *Clin Biomech (Bristol, Avon).* 2013;28(2):193-198.
8. Engebretsen L, Wijdicks CA, Anderson CJ, Westerhaus B, LaPrade RF. Evaluation of a simulated pivot shift test: a biomechanical study. *Knee Surg Sports Traumatol Arthrosc.* 2012;20(4):698-702.
9. Goldsmith MT, Jansson KS, Smith SD, Engebretsen L, LaPrade RF, Wijdicks CA. Biomechanical comparison of anatomic single- and double-bundle anterior cruciate ligament reconstructions: an in vitro study. *Am J Sports Med.* 2013;41(7):1595-1604.
10. Gorin S, Paul DD, Wilkinson EJ. An anterior cruciate ligament and medial collateral ligament tear in a skeletally immature patient: a new technique to augment primary repair of the medial collateral ligament and an allograft reconstruction of the anterior cruciate ligament. *Arthroscopy.* 2003;19(10):21-26.
11. Griffith CJ, LaPrade RF, Johansen S, Armitage B, Wijdicks C, Engebretsen L. Medial knee injury: part 1, static function of the individual components of the main medial knee structures. *Am J Sports Med.* 2009;37(9):1762-1770.
12. Griffith CJ, Wijdicks CA, LaPrade RF, Armitage BM, Johansen S, Engebretsen L. Force measurements on the posterior oblique ligament and superficial medial collateral ligament proximal and distal divisions to applied loads. *Am J Sports Med.* 2009;37(1):140-148.
13. Grood ES, Noyes FR, Butler DL, Suntay WJ. Ligamentous and capsular restraints preventing straight medial and lateral laxity in intact human cadaver knees. *J Bone Joint Surg Am.* 1981;63(8):1257-1269.
14. Grood ES, Suntay WJ. A joint coordinate system for the clinical description of three-dimensional motions: application to the knee. *J Biomech Eng.* 1983;105(2):136-144.
15. Halewood C, Hirschmann MT, Newman S, Hleihil J, Chaimski G, Amis AA. The fixation strength of a novel ACL soft tissue graft fixation device compared with conventional interference screws: a biomechanical study in vitro. *Knee Surg Sports Traumatol Arthrosc.* 2011;19(4):559-567.
16. Halinen J, Lindahl J, Hirvensalo E. Range of motion and quadriceps muscle power after early surgical treatment of acute combined anterior cruciate and grade III medial collateral ligament injuries: a prospective randomized study. *J Bone Joint Surg Am.* 2009;91(6):1305-1312.
17. Harris AH, Fernandes-Taylor S, Giori N. "Not statistically different" does not necessarily mean "the same": the important but underappreciated distinction between difference and equivalence studies. *J Bone Joint Surg Am.* 2012;94(5):e29.
18. Hughston JC, Eilers AF. The role of the posterior oblique ligament in repairs of acute medial (collateral) ligament tears of the knee. *J Bone Joint Surg Am.* 1973;55(5):923-940.
19. Irrgang JJ, Ho H, Harner CD, Fu FH. Use of the International Knee Documentation Committee guidelines to assess outcome following anterior cruciate ligament reconstruction. *Knee Surg Sports Traumatol Arthrosc.* 1998;6(2):107-114.
20. Jacobsen K. Stress radiographical measurement of the anteroposterior, medial and lateral stability of the knee joint. *Acta Orthop Scand.* 1976;47(3):335-344.
21. Jung HJ, Fisher MB, Woo SL. Role of biomechanics in the understanding of normal, injured, and healing ligaments and tendons. *Sports Med Arthrosc Rehabil Ther Technol.* 2009;1(1):9.
22. Kanamori A, Zeminski J, Rudy TW, Li G, Fu FH, Woo SL. The effect of axial tibial torque on the function of the anterior cruciate ligament: a biomechanical study of a simulated pivot shift test. *Arthroscopy.* 2002;18(4):394-398.
23. Kennedy JC, Fowler PJ. Medial and anterior instability of the knee: an anatomical and clinical study using stress machines. *J Bone Joint Surg Am.* 1971;53(7):1257-1270.
24. Kleweno CP, Jacir AM, Gardner TR, Ahmad CS, Levine WN. Biomechanical evaluation of anterior cruciate ligament femoral fixation techniques. *Am J Sports Med.* 2009;37(2):339-345.
25. LaPrade RF, Bernhardt AS, Griffith CJ, Macalena JA, Wijdicks CA. Correlation of valgus stress radiographs with medial knee ligament injuries: an in vitro biomechanical study. *Am J Sports Med.* 2010;38(2):330-338.
26. LaPrade RF, Engebretsen AH, Ly TV, Johansen S, Wentorf FA, Engebretsen L. The anatomy of the medial part of the knee. *J Bone Joint Surg Am.* 2007;89(9):2000-2010.
27. LaPrade RF, Wijdicks CA. The management of injuries to the medial side of the knee. *J Orthop Sports Phys Ther.* 2012;42(3):221-233.
28. LaPrade RF, Wijdicks CA. Surgical technique: development of an anatomic medial knee reconstruction. *Clin Orthop Relat Res.* 2012;470(3):806-814.
29. Lind M, Jakobsen BW, Lund B, Hansen MS, Abdallah O, Christiansen SE. Anatomical reconstruction of the medial collateral ligament and posteromedial corner of the knee in patients with chronic medial collateral ligament instability. *Am J Sports Med.* 2009;37(6):1116-1122.
30. Malanga GA, Andrus S, Nadler SF, McLean J. Physical examination of the knee: a review of the original test description and scientific validity of common orthopedic tests. *Arch Phys Med Rehabil.* 2003;84(4):592-603.
31. Mauck H. A new operative procedure for instability of the knee. *J Bone Joint Surg Am.* 1936;18:984-990.
32. O'Donoghue DH. Reconstruction for medial instability of the knee. *J Bone Joint Surg Am.* 1973;55(5):941-954.
33. Robinson JR, Bull AM, Thomas RR, Amis AA. The role of the medial collateral ligament and posteromedial capsule in controlling knee laxity. *Am J Sports Med.* 2006;34(11):1815-1823.
34. Slocum DB, Larson RL. Rotatory instability of the knee: its pathogenesis and a clinical test to demonstrate its presence. *J Bone Joint Surg Am.* 1968;50(2):211-225.
35. Tzurbakis M, Diamantopoulos A, Xenakis T, Georgoulis A. Surgical treatment of multiple knee ligament injuries in 44 patients: 2-8 years follow-up results. *Knee Surg Sports Traumatol Arthrosc.* 2006;14(8):739-749.
36. Umansky AL. The Milch fasciodesis for the reconstruction of the tibial collateral ligament. *J Bone Joint Surg Am.* 1952;34(1):202-206.
37. Warren LA, Marshall JL, Girgis F. The prime static stabilizer of the medial side of the knee. *J Bone Joint Surg Am.* 1974;56(4):665-674.
38. Wijdicks CA, Brand EJ, Nuckley DJ, Johansen S, LaPrade RF, Engebretsen L. Biomechanical evaluation of a medial knee reconstruction with comparison of bioabsorbable interference screw constructs and optimization with a cortical button. *Knee Surg Sports Traumatol Arthrosc.* 2010;18(11):1532-1541.
39. Wijdicks CA, Griffith CJ, Johansen S, Engebretsen L, LaPrade RF. Injuries to the medial collateral ligament and associated medial structures of the knee. *J Bone Joint Surg Am.* 2010;92(5):1266-1280.
40. Wijdicks CA, Griffith CJ, LaPrade RF, et al. Medial knee injury: part 2, load sharing between the posterior oblique ligament and superficial medial collateral ligament. *Am J Sports Med.* 2009;37(9):1771-1776.
41. Wu G, Cavanagh PR. ISB recommendations for standardization in the reporting of kinematic data. *J Biomech.* 1995;28(10):1257-1261.
42. Yamamoto Y, Hsu WH, Woo SL, Van Scyoc AH, Takakura Y, Debski RE. Knee stability and graft function after anterior cruciate ligament reconstruction: a comparison of a lateral and an anatomical femoral tunnel placement. *Am J Sports Med.* 2004;32(8):1825-1832.
43. Yoshiya S, Kuroda R, Mizuno K, Yamamoto T, Kurosaka M. Medial collateral ligament reconstruction using autogenous hamstring tendons: technique and results in initial cases. *Am J Sports Med.* 2005;33(9):1380-1385.